

Secondary Subfertility after Conservative Surgical Management (B-Lynch Suture) of Intractable Post Partum Haemorrhage

Farhat Arshad,¹ Shazia Syed²

¹Consultant Obstetrician and Gynaecologist, ²Senior Registrar, Department of Obstetrics and Gynaecology, unit-I, Holy Family Hospital, Rawalpindi.

Correspondence: Dr. Shazia Syed. Senior Registrar, Department of Obstetrics and Gynaecology, Unit-I, Holy Family Hospital, Rawalpindi.
Email: drshazee@hotmail.com

Abstract

Various medical and surgical treatment modalities are available for post partum haemorrhage. B-Lynch Brace suture, a conservative surgical modality is being used now a days, worldwide. Whereas this expertise is simple, safe, quick and life saving, it is not without few very serious but fortunately rare complications. Here is described a case with uterine necrosis and adhesions leading to subfertility in a woman, as a long term complication of B lynch suture, applied for the management of post-partum haemorrhage in her last delivery.

Key words: Post-partum haemorrhage, B-lynch suture, Uterine necrosis, Hysterectomy.

Introduction

Obstetric haemorrhage is one of the major causes of maternal deaths both in developed and developing countries. In the 2003-2005 report of the UK Confidential Enquiries into Maternal Deaths, obstetric haemorrhage was the third highest direct cause of maternal death.¹

Primary Post Partum Haemorrhage (PPH) defined as haemorrhage within 24 hours of delivery occurs in 4% to 6% of pregnancies and in 80% cases uterine atony is the main cause.² Various medical and sur-

gical techniques are recommended to control bleeding in primary PPH. These include bimanual uterine compression, the use of a variety of uterotonic agents, vaginal and uterine exploration, uterine tamponade using balloons or packing, uterine and hypogastric artery ligation, B-Lynch (Brace) suture, uterine artery embolization and hysterectomy.^{3,4}

Case Report

A 25 years old lady, P1+0 married for 8yrs presented with history of secondary sub fertility for last 6 yrs. Her last delivery was 6yrs back via spontaneous ver-

tex delivery at a tertiary care hospital. It was followed by primary PPH due to uterine atony, which was not settled by uterotonic medications. So an exploratory laparotomy was planned and B-Lynch Brace suture was applied to control bleeding. Her post operative period however, remained uneventful.

For her secondary subfertility baseline investigations were done. Her hormonal profile and husband's semen analysis were normal. Her HSG could not be done due to a very high up cervix, so examination under anaesthesia (EUA), diagnostic Laparoscopy and tubal patency test was planned.

On EUA cervix was high up and could not be visualized vaginally. On laparoscopy there were dense adhesions between uterine fundus and anterior abdominal wall, pulling the uterus high, out of the pelvis. After adhesiolysis uterus fell back within the pelvis, making the cervix approachable vaginally. Uterine sound was passed but only after 4 cm within the uterine cavity, sound was seen in the abdominal cavity due to iatrogenic perforation through the site of adhesions (Figure 1). There was also impression of a thick septum dividing the uterine cavity into two halves, giving the uterus a bi-lobed appearance externally (Figure 2). As uterine perforation was not bleeding so it was left as such. Foley's catheter balloon was inflated within the uterine cavity and was removed later on 5th post operative day. On tubal patency test, there was no spillage of dye from either tube; instead there was extravasation of dye in left broad ligament and free dye spillage from uterine perforation (Figure 3). Both ovaries were however normal. Patient was counseled regarding poor prospects of fertility and risk of uterine rupture, if she conceives subsequently.

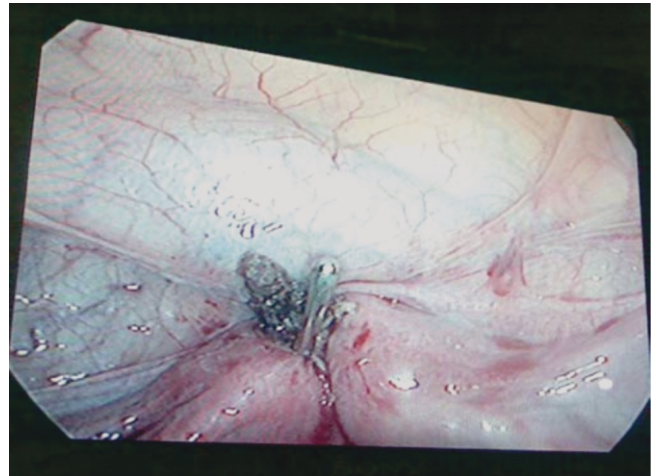


Figure 1. Uterine sound coming out of perforation.

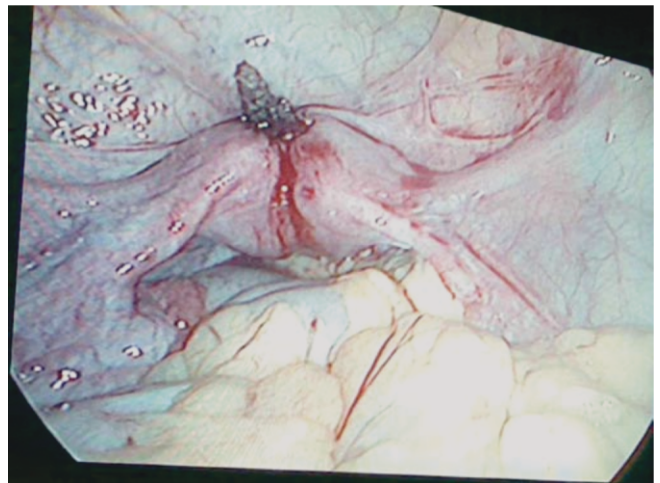


Figure 2. Bilobed uterus due to adhesions.

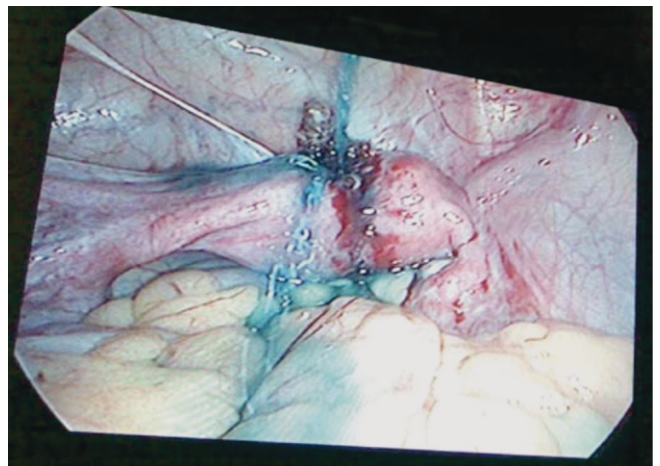


Figure 3. Extravasation of dye from perforation.

Discussion

Known risk factors for PPH due to uterine atony are multiparity, uterine overdistension (fetal macrosomia, multiple pregnancy, polyhydramnios), prolonged or augmented labour, precipitate labour, maternal obesity, operative delivery, chorioamnionitis, operative vaginal delivery and a history of PPH.³ The management of PPH requires early recognition, rapid action and most importantly, a multidisciplinary approach. Approximately one third of women with PPH unresponsive to uterotonic agents will have hysterectomy and one quarter of these women are nulliparous.⁴ The compression suture (B-Lynch) techniques have shown great promise in decreasing maternal morbidity and mortality associated with uterine atony, while preserving the uterus⁵ for subsequent menstrual function and pregnancies.⁶ The advantages of the B-Lynch suture are that it is simple to perform, requires little operating time and less skill, than stepwise uterine devascularisation procedures which are not feasible all the time. In 2000, Ferguson raised concerns about the possible uterine damage following excessive uterine compression used in the B-Lynch technique.⁷ Hani Akouri and Christopher Shermine case report is the first to describe focal myometrial necrosis following the use of simultaneous B-Lynch and Cho square sutures.⁸ Other investigators have reported cases of severe uterine necrosis following use of the B-Lynch suture. Our patient, however, did not manifest any unusual symptoms in the immediate or late postpartum period after application of the compression suture.

Joshi⁹ described a case of B-Lynch suture in severe postpartum hemorrhage in a 26-year-old primigravida after caesarean section, who due to suspicion of

intra abdominal bleeding underwent laparotomy in the immediate postoperative period and it was found that B-Lynch suture had cut through and become embedded in the uterine wall, causing ischemic congestion and distension of the mid-section of the uterus between the B-Lynch vertical braces, giving the uterus a lobulated appearance.

Treloar reported the use of the B-Lynch suture to control severe PPH in a 33-year-old multigravida. Over the following three postpartum weeks, that lady experienced persistent vaginal bleeding and was found to have a tender sub-involuted uterus of 18-weeks' size. Multi planner multi sequence magnetic resonance imaging with and without intravenous Gadolinium contrast demonstrated an avascular uterus, except at the peripheral rim of the uterine wall.¹⁰ Unlike our patient, these two women were symptomatic in the postpartum period and underwent hysterectomy.

Excessive folding of the uterine wall produced by the compressive forces of the suture could conceivably produce unpredictable effects on the myometrial and endometrial vasculature and can give the uterus a bilobed appearance externally and intra uterine synechiae and some necrosis of tissue which can form adhesion with anterior abdominal wall, as in our case.

Patients who continue to have uterine tenderness or persistent vaginal bleeding following the application of the pressure suture should be investigated to rule out the possibility of uterine wall necrosis. Few authors have attributed this complication to the delayed absorption type of suture used and recommend the use of rapidly absorbable sutures.¹¹

As in our patient, Baskett observed the presence of grooves over the uterine fundus at the site of the

previous B-Lynch suture in three of the seven patients who had a subsequent CS after the initial compression suture. In two of these three cases, there were additional signs of minor ischemic necrosis: a whitened myometrium between the grooves at the fundus and puckering at the posterior entry and exit sites of the previous B-Lynch suture.¹² Same was the finding in our case. These cases suggest that the pressure produced by the compression sutures could cause progressive myometrial ischemic necrosis ranging from mild^{11,12} to complete myometrial necrosis.^{9,10}

In the early postpartum days, the uterus involutes much faster than the decreasing tensile strength of any type of suture used, and therefore as the uterus decreases in size the suture should become less applied to the uterine wall and should exert less pressure on the myometrium. The damage caused by the pressure suture would therefore occur in the immediate postoperative period and would be related to the degree of tension and ischemia that the suture exerts on the myometrium.

Besides, the type of uterine suture used, especially suture with delayed absorption, in combination with ischemic pressure of the compression suture may have an important role in the development of uterine synechiae. Another case report describes a case of secondary infertility due to the development of severe Asherman Syndrome after the B-Lynch compression suture and uterine artery ligation.¹³ Our patient had escaped immediate severe post partum uterine necrosis but could not escape intrauterine synechiae and presented with secondary subfertility.

Conclusions

Compression sutures are relatively simple to perform, effectively control postpartum haemorrhage due to uterine atony and allow fertility to be maintained. However women requiring compression sutures should be provided with information about possible complications. We also suggest postoperative follow-up for these women, which includes pelvic ultrasound and sonohysterography to identify uterine wall defects or uterine cavity adhesions. Three-dimensional ultrasound with or without MRI would be valuable in examining the integrity of the uterine wall. As the obstetrical community gains more experience with this novel technique, there will be better understanding of its effectiveness and complications will be identified. To facilitate this we suggest meticulous documentation of both successful and unsuccessful applications of compression sutures, as well as its short-term and long-term complications, if any.

References

1. CEMACH - Saving Mothers' Lives; Confidential Enquiry into Maternal and Child Health (CEMACH) - Reviewing maternal deaths to make motherhood safer 2003-2005 Executive Summary; (2003-2005), December 2007.
2. Magann EF, Evans S, Hutchinson M. Postpartum hemorrhage after vaginal birth: an analysis of risk factors. *South Med J.* 2005;98(4):419-422.
3. Royal College of Obstetricians and Gynaecologists, Green-top Guideline No.52. Prevention and Management of Postpartum Haemorrhages. May 2009.
4. El-Hamamy E, B-Lynch C. A worldwide review of the uses of the uterine compression suture techniques as alternative to hysterectomy in the management of severe post-

- partum haemorrhage. *J ObstetGynaecol* 2005;25:143–149.
5. Wohlmuth CT, Gumbs J, Quebral-Lvie B-Lynch : a case series. *Int J Fertile Women Med.* 2005;51(4):154-156.
 6. Tsitlakidis C, AlaladeA, Danso D, B-Lynch C.Ten year follow-up of the effect of the B-Lynch uterine compression suture for massive postpartum hemorrhage.*Int J FertilWomens Med.* 2006;51(6):262-265.
 7. Ferguson JE, Bourgeois FJ, Underwood PB. B-Lynch for postpartum haemorrhage.*ObstetGynecol* 2000;95:1020–1022.
 8. Akouri H, Sherman C. Uterine Wall Partial Thickness Necrosis Following Combined B-Lynch and Cho Square Sutures for the Treatment of Primary Postpartum Hemorrhage.*J ObstetGynaecol*2008;30(5):421–424.
 9. Joshi VM, Shrivastava M. Partial ischaemic necrosis of the uterus following a uterine brace compression suture. *BJOG* 2004;111:279–280.
 10. Treloar EJ, Anderson RS, Andrews HS, Bailey JL.Uterine necrosis following B-Lynch suture for primary postpartum hemorrhage. *BJOG* 2006;4:486–488.
 11. Grotegut C, Larsen F, Jones M, Livingston E. Erosion of a B-Lynch suture through the uterine wall. *J Reprod Med* 2004;49:849–852.
 12. Baskett TF. Uterine compression sutures for postpartum hemorrhage: efficacy, morbidity, and subsequent pregnancy.*ObstetGynecol* 2007;110:68–71.
 13. Goojha CA, Case A, Pierson R. Development of Asherman syndrome after conservative surgical management of intractable postpartum haemorrhage.*FertilSteril.* 2010;94(3):1098.e1-5.

Editors have tried their best to establish accuracy of the manuscripts, they however cannot be held responsible for the views expressed or conclusions drawn by the authors.